



A COMPARATIVE EVALUATION OF LEVOBUPIVACAINE WITH DEXMEDETOMIDINE AND LEVOBUPIVACAINE WITH FENTANYL IN THORACOTOMY FOR POST -OP ANALGESIA THROUGH THORACIC EPIDURAL

Anaesthesiology

Dr. Varun Kumar Assist. Proff. Dept. Anaesthesia S.N.M.C

Dr. Dinesh Singh Professor Dept. Anaesthesia, KGMU

T. C Pippal Professor Dept. Anaesthesia, F.H. Medical College

ABSTRACT

Background: Thoracotomy is known to cause intense postoperative pain, leading to compromised respiratory function, delayed ambulation, and increased morbidity. Thoracic epidural analgesia (TEA) remains the gold standard for postoperative pain management. Levobupivacaine, an S-enantiomer of bupivacaine, has a better safety profile. Adjuvants like fentanyl, a μ -opioid agonist, and dexmedetomidine, a selective α_2 -adrenergic agonist, are often added to enhance analgesic effect, though their comparative efficacy in thoracic surgery remains under-explored. **Objectives:** To compare the analgesic efficacy, sedation level, hemodynamic stability, and side-effect profile of levobupivacaine combined with dexmedetomidine versus levobupivacaine with fentanyl for thoracic epidural analgesia in post-thoracotomy patients. **Methods:** This prospective, randomized, double-blind study included 60 adult patients (ASA I/II) undergoing elective thoracotomy. Group A received 0.125% levobupivacaine with dexmedetomidine (1 $\mu\text{g}/\text{kg}$), while Group B received 0.125% levobupivacaine with fentanyl (1 $\mu\text{g}/\text{kg}$). Parameters recorded included VAS scores, Ramsay Sedation Score, first top-up time, total analgesic requirement, hemodynamic variables, and postoperative complications over 24 hours. **Results:** Group A showed significantly longer time to first top-up (346.07 ± 23.23 min), fewer top-ups, lower total analgesic requirement, better hemodynamic control, and lower VAS scores. Sedation was more pronounced with dexmedetomidine. Incidence of pruritus and nausea was significantly higher in Group B. No cases of bradycardia, hypotension, respiratory depression, or urinary retention were noted. **Conclusion:** Levobupivacaine with dexmedetomidine offers superior postoperative analgesia, greater hemodynamic stability, enhanced sedation, and fewer opioid-related side effects compared to fentanyl, making it a more effective epidural adjuvant for thoracotomy.

KEYWORDS

Thoracic Epidural Analgesia; Dexmedetomidine; Fentanyl; Postoperative Pain; Thoracotomy

INTRODUCTION

Thoracotomy is recognized as one of the most painful surgical procedures, with post-thoracotomy pain often described as severe and prolonged, leading to impaired pulmonary function, delayed ambulation, and risk of chronic pain syndromes if not managed effectively.¹ Globally, an estimated 2.5 to 3 million thoracic surgeries are performed annually, with an increasing number in India due to rising incidence of thoracic malignancies and trauma-related chest interventions.²

Thoracic epidural analgesia (TEA) is widely considered the gold standard for managing post-thoracotomy pain, offering superior pain control, improved oxygenation, and reduced postoperative pulmonary complications.³ Levobupivacaine, a pure S(-)-enantiomer of bupivacaine, has largely replaced its racemic counterpart due to its reduced cardiotoxicity and neurotoxicity while maintaining similar anesthetic efficacy.⁴

To enhance the quality and duration of analgesia, adjuvants such as opioids and α_2 -agonists are frequently co-administered. Fentanyl, a potent μ -opioid receptor agonist, offers rapid onset and effective analgesia but is limited by opioid-related side effects such as nausea, pruritus, respiratory depression, and tolerance.⁵ In contrast, dexmedetomidine, a highly selective α_2 -adrenergic agonist, provides analgesia, sedation, and opioid-sparing effects without respiratory compromise, making it a favorable alternative.⁶

Despite widespread use, direct comparisons of these two combinations—levobupivacaine with dexmedetomidine versus levobupivacaine with fentanyl—specifically for thoracic epidural analgesia in thoracotomy patients, remain limited. Therefore, the purpose of the study was to comparatively evaluate their analgesic efficacy, hemodynamic stability, sedation, rescue analgesic requirement, and adverse effect profile, thereby providing evidence-based guidance for optimal postoperative pain management in thoracic surgery.

MATERIALS AND METHODS

This randomized, double-blind, comparative study was conducted at King George's Medical University (KGMU), Lucknow, after obtaining ethical clearance from the Institutional Ethics Committee. Sixty adult patients aged 18–50 years, ASA physical status I or II, undergoing elective anterolateral thoracotomy were enrolled after written informed consent.

Inclusion Criteria

- Age 18–50 years
- ASA Grade I or II
- Body weight and height within $\pm 30\%$ of ideal values
- Consent for participation

Exclusion Criteria

- Use of analgesics, steroids, or opioids
- Allergy to study drugs
- Contraindication to regional anesthesia
- Inability to communicate
- Planned postoperative mechanical ventilation

Patients were randomly allocated to two equal groups using a computer-generated table. Group L-F received 9 mL of 0.125% levobupivacaine + 1 mL fentanyl (1 $\mu\text{g}/\text{kg}$), while Group L-D received 9 mL of 0.125% levobupivacaine + 1 mL dexmedetomidine (1 $\mu\text{g}/\text{kg}$). The epidural catheter was placed at the T6–T7 interspace under aseptic precautions.

All patients were premedicated with ondansetron 4 mg, fentanyl 100 μg , and glycopyrrolate 0.2 mg. Induction was done using propofol (2 mg/kg) and succinylcholine (2 mg/kg), followed by maintenance with halothane, nitrous oxide, and vecuronium. The epidural bolus was administered 20 minutes before extubation.

Postoperatively, a blinded observer monitored heart rate, MAP, and SpO_2 every 10 minutes for 30 minutes and then every 2 hours for 24 hours. Pain and sedation were assessed using the Visual Analogue Scale (VAS) and Ramsay Sedation Score (RSS), respectively.

Hypotension (MAP < 65 mmHg), bradycardia (HR < 50 bpm), and hypoxia (SpO_2 < 94%) were managed with standard protocols. Inadequate analgesia was treated with IV paracetamol 1 g.

Sample size was calculated based on a 2 ± 2 VAS difference with 80% power, resulting in 30 patients per group.

RESULTS

In our study, Group A and Group B were demographically comparable in age, height, weight, and BMI with no statistically significant difference, confirming effective randomization. This ensures that outcome differences are not attributable to baseline physical characteristics (See Table 1).

Table 1: Demographic & Anthropometric Profile

Variable	Group A	Group B
	Mean ±SD	Mean ±SD
Age (years)	30.30±3.39	30.73±3.51
Statistical significance	F=0.338 (ANOVA); p=0.798 (NS)	
Height (cm)	167.43 ±5.17	165.50±5.46
Weight (kg)	59.50±3.12	59.10 ±2.93
BMI (kg/m ²)	21.28 ±1.68	21.64 ±1.71

Baseline hemodynamic values including HR, BP, MAP, and SpO₂ showed no significant intergroup differences, establishing pre-intervention uniformity. Only SpO₂ showed statistical significance (p=0.012) but remained clinically irrelevant (See Table 2).

Table 2: Inter-Group Comparison of Hemodynamic Variables at Baseline

	Group A (n=30)		Group B (n=30)		Statistical Significance	
	Mean	SD	Mean	SD	F	'p'
Heart Rate (per min)	89.60	2.25	90.77	6.78	0.361	0.781
Systolic BP (mm Hg)	121.40	6.40	121.47	6.64	0.131	0.941
Diastolic BP (mm Hg)	76.53	3.92	77.93	5.92	1.666	0.178
Mean Arterial Pressure (mm Hg)	91.43	3.14	92.30	3.14	1.917	0.131
SPO ₂	98.00	0.79	97.97	0.85	3.818	0.012

Heart rate remained more stable in Group A (Dexmedetomidine) across all time intervals, while Group B (Fentanyl) showed greater variability and higher peaks, especially post-extubation. This suggests superior autonomic modulation and hemodynamic stability with dexmedetomidine (See Figure 1).

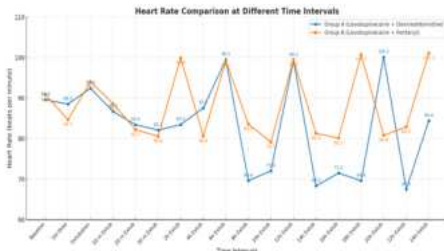


Figure 1: Heart Rate Comparison at Different Time Intervals

Systolic blood pressure remained more consistent in Group A (Dexmedetomidine) with fewer fluctuations, while Group B (Fentanyl) showed significantly higher variability and peaks, especially at 2h, 18h, and 24h post-extubation. This reflects better hemodynamic control with dexmedetomidine throughout the postoperative period (See Figure 2).

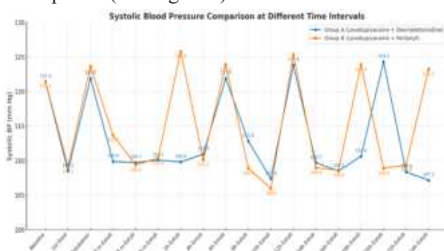


Figure 2: Systolic Blood Pressure Comparison at Different Time Intervals

Group A (Dexmedetomidine) demonstrated more stable and consistently lower diastolic blood pressure compared to Group B (Fentanyl), which showed significant elevations at several intervals. This suggests better hemodynamic stability with dexmedetomidine in the postoperative period (See Figure 3).

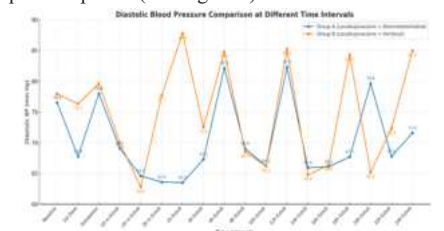


Figure 3: Diastolic Blood Pressure Comparison at Different Time Intervals

Mean arterial pressure (MAP) remained more stable in Group A (levobupivacaine with dexmedetomidine), while Group B (levobupivacaine with fentanyl) showed significant MAP fluctuations, especially at 2h and 24h post-extubation. These variations were statistically significant at most intervals (p<0.001), indicating better hemodynamic stability with dexmedetomidine (See Figure 4).

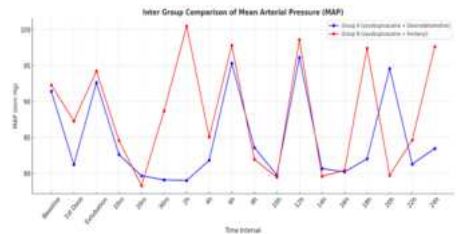


Figure 4: Mean Arterial Pressure (MAP)

Both Group A and Group B maintained stable and comparable SPO₂ levels throughout the 24-hour postoperative period. No statistically significant hypoxia was observed, indicating effective respiratory function and adequate analgesic management in both groups (See Figure 5).



Figure 5: Comparison of SPO₂ at Different Time Intervals

Group A consistently demonstrated lower VAS scores compared to Group B across most time intervals, indicating superior and sustained postoperative analgesia. Statistically significant differences (p < 0.001) were observed, especially at 2, 12, 18, and 24 hours, favoring dexmedetomidine as an adjuvant (See Figure 6).




Figure 6: VAS Score Comparison at Different Time Intervals

The RSS scores were consistently higher in Group A (Levobupivacaine + Dexmedetomidine) compared to Group B (Levobupivacaine + Fentanyl), indicating deeper and more prolonged sedation in the dexmedetomidine group. Statistically significant differences (p < 0.001) were observed at almost all intervals (See Figure 7).

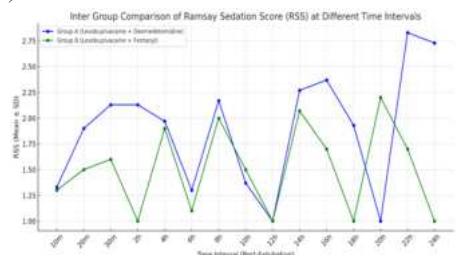


Figure 7: Comparison of Ramsay Sedation Score (RSS) at Different Time Intervals

Group A had a significantly longer time to first top-up, fewer top-ups, and lower total analgesic consumption (p<0.001). These findings

confirm dexmedetomidine's superior analgesic efficacy and duration (See Table 3).

Table 3: Inter Group Comparison Of Analgesic Properties

	Group A (n=30)		Group B (n=30)		Statistical Significance	
	Mean	SD	Mean	SD	F	'p'
Ist Topup Time (min)	346.07	23.23	114.87	4.85	1013.661	<0.001
Total Topups	3.10	0.31	5.10	0.31	356.447	<0.001
Total dose (mg)	34.88	3.43	57.38	3.43	356.447	<0.001

Group A had no reported complications, while Group B had higher rates of nausea (20%) and pruritis (26.67%) ($p < 0.001$). This highlights the opioid-related side effects in the fentanyl group and better safety with dexmedetomidine (See Table 4).

Table 4: Inter Group Comparison Of Complications

	Group A (n=30)		Group B (n=30)		Statistical Significance	
	No.	%	No.	%	X ²	'p'
Nausea & Vomiting	0	0.00	6	20.00	9.970	0.019
Bradycardia	0	0.00	0	0.00	—	—
Hypo-tension	0	0.00	0	0.00	3.025	0.388
Pruritis	0	0.00	8	26.67	25.714	<0.001
Urinary retention	0	0.00	0	0.00	—	—
Respiratory depression	0	0.00	0	0.00	—	—
Heart Block	0	0.00	0	0.00	—	—
Rescue analgesia	1	3.33	4	13.33	3.019	0.389

DISCUSSION

The demographic and anthropometric profiles of Groups A and B were comparable, with no statistically significant differences in age, height, weight, or BMI, confirming effective randomization. This baseline homogeneity mirrors findings by Sedky et al.⁷, Mukherjee et al.⁸, and Patil et al.⁹, where groups receiving dexmedetomidine and clonidine or opioids were similarly matched demographically. Hemodynamic parameters including heart rate, blood pressure, and MAP were also comparable at baseline, in line with Mukherjee et al.⁸ and Ramkiran et al.⁶, supporting the internal validity of the intervention.

Postoperatively, Group A (dexmedetomidine) showed significantly greater hemodynamic stability, with lower heart rate and blood pressure fluctuations compared to Group B (fentanyl). This finding is supported by Singh et al.¹⁰, and Mohan et al.¹¹, who reported enhanced autonomic control with dexmedetomidine. In contrast, the fentanyl group experienced greater sympathetic surges, consistent with Patil et al.⁹ and Mohammad et al.¹². MAP values also favored dexmedetomidine, showing smoother trends across time points, reflecting its central α_2 -agonist action and corroborating the results of Sedky et al.⁷.

Pain control was significantly superior in Group A, with lower VAS scores across all time points and a prolonged first top-up time (346.07 ± 23.23 min vs. 114.87 ± 4.85 min; $p < 0.001$), fewer top-ups, and lower total analgesic dose. These results align with studies by Concha et al.¹³, Ganesh et al.¹⁴, and Licker et al.¹⁵, highlighting the prolonged and effective analgesic action of dexmedetomidine. Additionally, Ramsay Sedation Scores were consistently higher in Group A, indicating better sedation without respiratory compromise, a benefit noted in studies by Sedky et al.⁷.

In terms of complications, Group A had no reported adverse effects, while Group B showed significantly higher incidence of pruritis (26.67%) and nausea/vomiting (20%), consistent with opioid-related side effects observed by Patil et al.⁹ and Bajwa S et al.¹⁶. No respiratory depression or hemodynamic compromise was observed in either group, indicating overall safety of both agents when used appropriately.

CONCLUSION

We concluded that the use of dexmedetomidine as an adjuvant in regional anesthesia offers superior analgesic benefits over fentanyl. It significantly prolongs the duration of pain relief, reduces the need for supplemental analgesia, and provides more stable hemodynamic parameters. Moreover, patients experienced fewer opioid-related side effects, indicating a safer postoperative profile. These findings highlight dexmedetomidine as a clinically advantageous alternative, particularly for enhancing analgesic efficacy and minimizing adverse

events in patients undergoing laparoscopic cholecystectomy.

REFERENCES

- Wang L, Yang M, Meng W. Prevalence and characteristics of persistent postoperative pain after thoracic surgery: a systematic review and meta-analysis. *Anesthesia & Analgesia*. 2023 Jul 1;137(1):48-57.
- Sultanpuram S, Alaparthy GK, Krishnakumar SK, Ottayil ZC. Physiotherapy practice patterns for management of patients undergoing thoracic surgeries in India: a survey. *Surgery research and practice*. 2016;2016(1):9717489.
- Yeung JH, Gates S, Naidu BV, Wilson MJ, Smith FG. Paravertebral block versus thoracic epidural for patients undergoing thoracotomy. *Cochrane Database of Systematic Reviews*. 2016(2).
- Ture P, Ramaswamy AH, Shaikh SI, Alur JB, Ture AV. Comparative evaluation of anaesthetic efficacy and haemodynamic effects of a combination of isobaric bupivacaine with buprenorphine vs. isobaric levobupivacaine with buprenorphine for spinal anaesthesia—A double blinded randomised clinical trial. *Indian journal of anaesthesia*. 2019 Jan 1;63(1):49-54.
- Sun S, Wang J, Bao N, Chen Y, Wang J. Comparison of dexmedetomidine and fentanyl as local anesthetic adjuvants in spinal anesthesia: a systematic review and meta-analysis of randomized controlled trials. *Drug design, development and therapy*. 2017 Dec 1;3413-24.
- Martin MF, Lopez SA, Alvarez-Santullano CA. Role of adjuvants in regional anesthesia: a systematic review. *Revista Española de Anestesiología y Reanimación (English Edition)*. 2023 Feb 1;70(2):97-107.
- Sedky AM, Yahia MF, Helal SM, Doha NM, Habib RM, Donya SS. Comparative study between the effects of either dexmedetomidine or clonidine when combined with bupivacaine in thoracic epidural anaesthesia in patient undergoing thoracotomy. *Biol Theory*. 2015;3:739-55.
- Mukherjee A, Das A, Mayur N, Bhattacharyya C, Biswas H, Mitra T, Roybasunia S, Mandal SK. Comparative evaluation of analgesic sparing efficacy between dexmedetomidine and clonidine used as adjuvant to ropivacaine in thoracic paravertebral block for patients undergoing breast cancer surgery: a prospective, randomized, double-blind study. *Saudi Journal of Anaesthesia*. 2018 Oct 1;12(4):548-54.
- Patil TS, Arora N, Kulkarni J, Omar SM. To Compare The Efficacy of Epidural Ropivacaine With Ropivacaine Plus Dexmedetomidine For Postoperative Analgesia in Thoracic Surgeries. *Annals of International Medical and Dental Research*. 3(3):1.
- S, Arora V, Kaur J, Singh A, Parmar SS. Comparative evaluation of dexmedetomidine and fentanyl for epidural analgesia in lower limb orthopedic surgeries - Saudi J Anaesth. 2011; 5: 365-370.
- Mohan SV, Berry PD, Jackson M. Thoracic epidural infusions for post-thoracotomy pain: a comparison of fentanyl-bupivacaine mixtures vs. fentanyl alone. *Anaesthesia* 2010; 54: 641-646
- Mohamed AA, Fares KM, Mohamed SA. Efficacy of intrathecally administered dexmedetomidine versus dexmedetomidine with fentanyl in patients undergoing 87 major abdominal cancer surgery. *Pain Physician*. 2012; 15(4): 339-48.
- Concha M, Dagnino MD, Cariaga M. Analgesia after thoracotomy: epidural fentanyl/bupivacaine compared with intercostal nerve block plus intravenous morphine. *J Cardiothorac Vasc Anesth* 2004; 18(3): 322-326.
- Ganesh A, Adzick NS, Foster T, Cucchiario G. Efficacy of addition of fentanyl to epidural bupivacaine on postoperative analgesia after thoracotomy for lung resection in infants. *Anesthesiology*. 2008;109(5): 890-4.
- Licker M, Spiliopoulos A, Tschopp JM. Influence of thoracic epidural analgesia on cardiovascular autonomic control after thoracic surgery. *Br J Anaesth*. 2003; 91(4): 525-31.
- Bajwa S, Sukhwinder Kaur Bajwa, Jasbir Kaur. Dexmedetomidine and clonidine in epidural anaesthesia: A comparative evaluation. *Indian J Anaesth*. 2011; 55(2): 116-121.